Neurosurgery Compact II

A Comprehensively Analyzed Work

Second Edition
Spring 2023

Neuro-Oncology
Functional NeuroSurgery
Minimally invasive
Degenerative Diseases of Spinal Column
Common Disease of CNS
Neuro Rehabilitation
Electrophysiology

[History, Diagnostic, Therapy]

By
Armin A. Norousi M.D
Jalal J. Shokouhi M.D.

Read More

Armin A. Norusi M.D.
Neurosurgeon

Head of Spine Care /MVZ, Berlin, Germany
Guest Professor in the University Lemberg / UKs
Chairman of international Europe-Middle-East Neurocongress
CEO & Founder of International Education Center e. V. (IEC e. V.), Munich, Germany
www.sinapublisher.com
info@sinapublisher.com
Book.neurosurgery@gmail.com

Jalal J. Shokouhi M.D.
Neuroradiologist

President of Iranian Society of Radiology
Founder of TBP Co. No.467, Hafez St. Tehran, Iran
Co-Founder of International Edecation Center e.V (IEC e. V.), Munich, Germany
Medical Manager of Koroush and Jaame-Jam imaging centers
www.Medimage.ir
www.Radioogle.ir
Jalaljalalshokouhi@hotmail.com



TO THOSE,
WHO ARE SUFFERING

Preface

Rapid advances in the field of CNS disorders have opened a new route of diagnostic and therapy in this field.

Knowledge of current concepts associated with vascular disorders of CNS around the world is a crucial issue for providing appropriate evaluation, referral and treatment of patients with vascular diseases of CNS.

The main goal of this book is to provide broad based current knowledge of diverse fields of vascular disorders of CNS on a high level.

The book contains a compact text from several neurosurgical sources consisting of many journals and books, which have been published currently in the neurosurgical field.

The topics have been arranged in Top Down starting from cerebral vascular disorders to the spine to provide the readers with sound knowledge base in the fundamentals of vascular anatomy, history, vascular imaging, clinical assessment and also operative and non-operative therapy of vascular disorders of CNS.

The text has been made spare and concise therefore it could be read quickly in the clinic during the patient rounds, daily work and also in the operating room.

We have created about 44 tables by ourselves in the hope to keep the readers attention to the essential points and to avoid unnecessary details.

In addition we have integrated about 71 suitable original photographs into the book. The most important clinical and radiological features were usually labeled and highlighted in color.

The intended audience will be wide ranging including from medical student, residents, fellows, of course neurosurgeons and neuroradiology.

The book may also be of interest to physicians and nurses working at the ICU as well as patients with vascular diseases of CNS.

We are especially grateful to Dr. A. Khadem for bringing this book to editorial and technical completion.

Armin A. Norusi M.D.
Neurosurgeon

Jalal J. Shokouhi M.D.
Neuroradiologist

Contents

General Classification of CNS Tumors.....14

Benign Lesions of Scalp..... 14
Seborrheic Keratosis 14
Keratoacanthomas..... 14
Malignant Lesions of Scalp 15
A- Primary Malignant Lesions 15
Basal cell Carcinoma (BCC) 15
Squamous Cell Carcinoma (SCC)..... 16
Melanoma..... 17
Secondary (Metastatic) Lesions of Scalp 19
Literatures..... 19

Skull Tumors.....21

General Histopathological Classification of Skull Tumors 21
Primary Tumor of Skull 25
Benign Skull Tumors 25
Osteomas 25
Chondromas (Osteochondromas) *(see also chapter of SB)* 27
Hemangiomas and Lymphangiomas 30
Epidermoid, Dermoid, Teratoma 31
Giant Cell Tumor (Osteoclastoma) 33
Aneurysmal Bone Cyst..... 34
Primary Malignant Tumors of Skull 34
Osteosarcomas 35
Fibro-sarcomas 35
Ewing's Sarcomas..... 36
Secondary Neoplasms of Skull (Metastatic lesions) 36
Direct Extension Neoplasm of Skull..... 37
Distant Spread Tumors of Skull..... 38
Carcinoma 39
Lymphoma..... 39
Plasmacytomas (Multiple Myeloma) 40
Neuroblastomas 42
Conditions Stimulating Skull Lesions..... 43
Paget's disease (Osteitis Deformans)..... 44
Hyperostosis frontalis interna 45
Eosinophilic granuloma..... 46
Leptomeningeal cyst 47
Osteomyelitic lesion..... 47
Sinus pericranii 47

Literatures 47
Tumors of Skull Base..... 50

General Histopathological Classification of the Tumors of Skull Base 50
Spenoidal Wing Meningioma (Osseous Meningioma).....53
Olfactory Groove Meningeomas 55
Glomus Jugulare Tumors (Paragangliomas).....55
Literatures 62
Chondromas (Osteochondromas)..... 64

Chondrosarcoma.....65
Fibrous Dysplasia.....67
Literatures 68
Tumors of Intracranial Components (CNS) 70

Neuroepithelial Tumors 70
Glial Tumors (WHO I-IV) 70
Astrocytomas 70
Oligodendroglial Tumors (WHO II-III) 72
Mixed Glioneural Neoplasms (WHO I).....75
Mixed Glio-neural Tumor, Unusual Rare Clial tumor (WHO I):.....75
Ependymal Cell Tumors (WHO II-III) 75
Epithelial Tumors 76
Primary CNS Lymphomas (PCNSL).....76
Meningeal Tumors 77
Pineal Tumors 78
Primitive Neuroectodermal Tumors (PNET) 78
Germ Cell Tumors.....80
Capillary Hemangioblastomas (WHO grade I) 81
Literatures 83
The Most Common Supratentorial Tumors 85

Clial Tumors 85
Litertures.....91
High-Grade Gliomas (WHO grade III-IV) 94

Literatures 99
Rare and Unusual Gliomas.....102

Pilocytic Astrocytomas.....102
Brain stem Gliomas 103
Subependymal Giant Cell Astrocytoma 105
Gangliogliomas 106
Desmoplastic Neuro-epithelial Tumors 107
Pleomorphic Xanthoastrocytomas.....108
Astroblastomas (controversial accepted glioma).....108

Hamartomas 109
Literatures 110
Intraventricular Tumors 113
General Consideration 113
Ependymomas 113
Choroid plexus Tumors 115
Colloid Cyst 118
Literatures 122
Lymphomas 125
Primary CNS Lymphoma (PCNSL) 125
Secondary Lymphoma of CNS (metastatic lymphoma) 128
Literature 129
Meningeal Tumors 132
I-Supratentorial Meningiomas 132
II-Infratentorial Meningiomas 132
General Consideration of Meningiomas 132
Supratentorial Meningiomas 135
Convexity meningiomas 137
Tentorial Meningiomas 137
Intraventricular Meningiomas (trigonal meningiomas) 138
Meningeal Sarcomas 139
Fibrosarcoma 139
Rhabdomyo-sarcoma 140
Mesenchymal Chondrosarcoma 140
Litertures 141
The Most Common Primary Midline Tumors 145
Tumors of Pineal Region 145
Pineal Tumors 145
Histological Classification of Pineal Tumors 146
Germ Cell Tumors 151
Primitive Neuroectodermal Tumors (PNET) 152
Literatures 153
Most primary Infratentorial Tumors 156
Infratentorial Meningiomas 156
Posterior Fossa Meningioma 156
CPA Meningiomas 156
Petroclival Meningiomas 156
Foramen Jugular Meningiomas 157
Foramen Magnum Meningiomas 158
Middle and Anterior Fossa Meningiomas 159
Tuberculum Sellae Meningioma 159

Diaphragma Sella Meningiomas 159
Cavernous Sinus Meningiomas 161
Optic Nerve Meningiomas 162
Olfactory groove Meningioas 163
Meningeal Haemangiopericytomas 165
Tumors of Posterior Fossa 167
Medulloblastoma 167
Literatures 172
CapillaryHaemangioblastomas (Haemangioblastoma) 175

Clear Cell Renal Cell Carcinoma (CCRCC) 178
Pheochromocytoma 179
Literatures 179
Acoustic Neurinoma (Schwannoma) 182

Literatures 187
Tumors of Middle Fossa (Sella Region) 190

Trigeminus Schwannomas 190
Literatures 194
Pituitary Tumors 197

Different Types of Pituitary Adenomas 204
Prolactinoma 204
Thyreotroph Adenoma 211

Pituitary Carcinomas 211
Pituitary Apoplexy 211
Literatures 212
Literatures 224
Most Common Tumors of Anterior Fossa 226

Olfactory Groove Meningiomas 226
Optic Nerve Gliomas 226
Literatures 229
Optic Nerve Gliomas 231

Literatures 233
Secondary Tumors of CNS (Cerebral Metastases) 235

Litertures 239
Cranio-Vertebral Tumors 241

Extradural Tumors of CVJ 241
Osteogenic Tumors (Osseous Tumors) 245
Osteoid Osteomas 245
Osteoblastomas (Giant Ostoids - Osteofibromas) 246
Osteoclastoma (Giant Cell Tumor) 247

Cartilagenous Tumors (Chondroblastic Tumors) 247
Osteochondromas..... 247
Chondrosarcoma 248
Osteosarcoma..... 249
Vascular Tumors..... 250
Haemangiomas 250
Aneurysmal Bone Cyst..... 251
Angiolipoma..... 253
Literatures..... 253
Malignant Tumors of CVJ & Vertebral Axis..... 255

Notochord Tumors (Chordoma) 255
Tumors with marrow origin..... 257
Literatures..... 260
Intradural extramedullary Tumors of CVJ 262

Meningiomas (Foramen Magnum Meningiomas) 262
Spinal Tumors..... 264
Literatures..... 265
Intradural Extramedullary Tumors of Spinal Collumn 266

Meningiomas 266
Nerve Sheath Neoplasms..... 268
Filum Terminale Ependymomas..... 269
Literatures..... 271
Intramedullary Tumors of Spinal Cord 274

Ependymomas..... 274
Astrocytomas..... 274
Haemangioblastomas 275
Miscellaneous Processes 275
Literatures..... 278
Spinal Metastases 280

Literatures..... 287
Functional Neurosurgery Section 291

Movement Disorder Syndromes 291
Parkinsonism 293
Essential Tremor (benign tremor a 4-8 –HZ) 297
Hyperkinetic Movement Disorders..... 299
Huntington's Disease (HD) 299
Literatures..... 309
Spasticity 312

Literatures..... 319
Torticollis Spasmodic (TS)..... **321**

Read More

Literatures 324
Facial Spasm 326
Literatures 328
Trigeminal Neuralgia (TN) 330
Literatures 334
Intractable Vertigo (Vestibular Disorders) 336
Introduction 336
Vertigo is the feeling that you or your environment is moving or spinning. 336
Literatures 339
Hyperhidrosis 341
Literatures 343
Minimally Invasive surgery 347
Principle of Radiotherapy 347
External Beam Radiotherapy (Tele-therapy) 347
Conventional Fractionated Radiotherapy (CFR) 348
Stereotactic Radiosurgery (SR) 349
Introduction 349
Principle of Radiosurgery 349
Radiobiology of RS 350
Heavy-particle Radiosurgery (charged particles radiosurgery): 350
Linac Radiosurgery 351
Principle of Linac 351
Gamma-Knife Radiosurgery 351
History 351
Cyber-Knife (Frameless Image Guided Radiosurgery) 352
Literatures 353
Endoscopic Surgery 355
Neuroendoscopy 355
History 355
Endoscopic Technology 355
Advantage of Endoscopic Procedure 356
Membrane Fenestration 356
Common Indications of Neuro-endoscopic Surgery 356
Tumor Biopsy 357
Ventricular Shunt 357
Literatures 360
Degenerative Disease of Spinal Column 362
Section of Degenerative Spine Diseases 363
Spondylosis and Spondylolisthesis (Spondylopathy) 363
Spondylosis 363

Read More

Spondylolisthesis 363
History 364
Literatures 378
Degenerative Spinal Canal Stenosis (SCS) 379
Cervical Spinal Stenosis (Cervical Myelopathy) (CM) 379
Introduction 379
History 379
Etiopathology 379
Secondary stenosis (acquired form) 379
Degenerative Cervical Stenosis 379
Incidence 380
Etio-pathology 380
Symptoms 381
Therapy 382
Surgery 383
Anterior approach 383
Posterior approach: 384
Outcome 384
Complications 385
Conclusion 385
Literatures 389
Degenerative Lumbar Stenosis (DLS) 391
Introduction 391
Symptoms 391
Diagnosis 391
MRI scans 391
Therapy 392
Conservative management 392
Surgical Intervention 392
Laminotomy: 392
Outcome 393
Complications 393
Introduction 394
Etiopathology 394
Symptoms 394
Therapy 395
Conservative 395
Surgical 395
Literatures 395
Degenerative Disc Disease (DDD) 396
Degenerative Disc Disease of Cervical Spine 396
Introduction 396

Read More

Incidence 396
History 396
Etiopathology 396
Symptoms 396
Cervical Myelopathy 397
Diagnosis 397
Myelography: 397
Therapy 397
Outcome 398
Conclusion 399
Literatures 399
Degenerative Disc Disease of the Thoracic Spine 401
Literatures 404
Degenerative Disc Disease of the Lumbar Spine 406

CT-Scan 408
Myelography 408
Operative: 410
Literatures 414
Common Diseases of CNS 416

Hydrocephalus 417
Pathophysiology of CSF production 418
Classification of Hydrocephalus 420

Communicating HCP (Non-obstructive HCP) 420
Non-communicating HCP (Obstructive HCP) 420
Normal Pressure Hydrocephalus (Compensated or Arrested HCP) 420
Diagnosis of Hydrocephalus in Children 422
Therapy of Hydrocephalus in Infants and Children 423

Literatures 426
Syringomyelia 427

Syringohydromyelia 427
Syringomyelia 427
Etiopathology 427
Literatures 429
Infection of CNS 431

Cerebral Infection 431
Cerebral Meningitis 431
Purulent Meningitis 432
Chronic Purulent Meningitis 433
Tuberculosis 433
TBC Meningitis 433

Literatures 435
Postoperative Shunt Infection 437
Literatures 438
Infection of the Spine and Spinal Cord 441
Pyogenic Spinal Infection 441
Medical Treatment: 442
Treatment of Epidural Abscesses 443
Postoperative Spine Infections 443
Literatures 444
Section of Degenerative Spine Diseases 446
Spondylosis and Spondylolisthesis (Spondylopathy) 446
Spondylosis 446
Spondylolisthesis 446
History 447
Literatures 451
Degenerative Spinal Canal Stenosis (SCS) 452
Cervical Spinal Stenosis (Cervical Myelopathy) (CM) 452
Literatures 458
Degenerative Lumbar Stenosis (DLS) 460
Lateral recess stenosis 463
Literatures 464
Degenerative Disc Disease (DDD) 464
Degenerative Disc Disease of Cervical Spine (DDDC) 465
Literatures 467
Degenerative Disc Disease of the Thoracic Spine 469
Introduction 469
Literatures 472
Degenerative Disc Disease of the Lumbar Spine (LDD) 474
Differential Diagnosis (DD): 476
Literatures 481
Neuro-Rehabilitation 485
Ambulatory Reha 486
Literatures 490

Neurophysiology (Clinical Neurophysiology) ……490
Electrophysiology (ephys)……490
Electroencephalography (EEG)……490
Electromyography (EMG)……493
Acknowledgement……501

NEURO-ONCOLOGY

General Classification of CNS Tumors

A- Cranial Tumors
B- Cranio-vertebral Junction Tumors
C- Spinal Tumors

Cranial Tumors

Scalp Tumors

Introduction

These are benign and malignant lesions of scalp layers restricted between supra-orbital ridge along the superior nutchal, zygoma and mastoid bone. A number of them are associated with chromosomal and genetic abnormalities, including those with neurofibromatosis Type I and II.

Benign Lesions of Scalp

Seborrheic Keratosis

a. **Seborrheic Keratosis**: It is a benign brown-colored lesion arising from the basal epithelial cells. In contrast with Actinic Keratosis, they don't become malignant. Therapy is more for cosmetic reasons or for obtaining diagnosis.

b- Actinic keratosis: Darkened or red areas with irregular borders with origin of epithelial transformation. These occur on parts of the skin exposed to radiation or extensive sunshine. It shows a tendency to malignancy.

Therapy: There are conservative topical agents such as (5-FU) and surgical procedure such as cryosurgery, shave excision, and carbon dioxide laser. Above therapy is recommended, because of tendency to become malignant.

Keratoacanthomas

These are rapid growth lesions with papillary origin and clinically confused lesions. Therefore obtaining a definitive diagnosis for performing the appropriate treatment is recommended.

Malignant Lesions of Scalp

A- Primary Malignant Lesions

Basal cell Carcinoma (BCC)

Introduction

A very common form of skin lesion arising from basal cells of epidermis and maybe becomes locally destructive. BCC may metastasize and lead to death.

Incidence

It accounts for about 25% of all cancers in the United States and 75% of all non-melanoma skin cancer. Risk factors are exposure to excessive sunshine, positive HIV, and also patients that have under-gone organ transplantation.

Etio-pathology

The BCC and squamous cell carcinoma (SCC) are staged by the tumor node metastasis (TNM) staging system of the American Joint Committee on Cancer (AJCC) based on the depth of lesion, and degree of cellular atypia.

There are several types of BCC shown in below table.

Tab. 1 shows the different type of BCC based on cellular atypia

- Nodular Type: It is a well-circumscribed lesion with different light or dark color and telangiectasic vessels
- It is most common types and appears in two subtypes: nodular or nodular ulcerative
- Superficial multi-centric Type
- Morphea Type is the third form of BCC

**BCC may be associated with squamous metaplasia, which is most aggressive and likely to metastasize.*

Read More

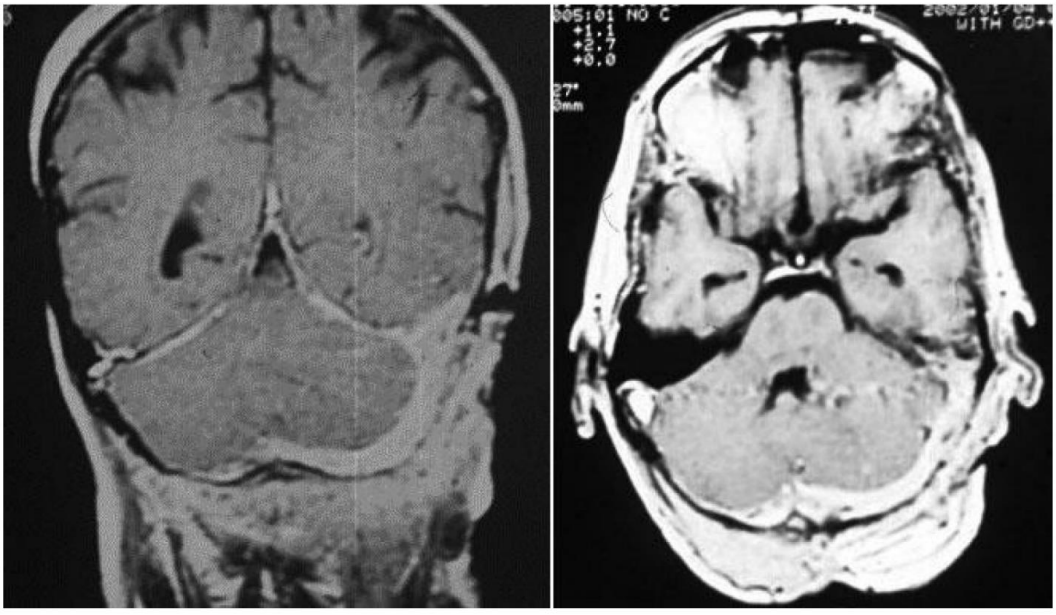

Fig. 1&2: Occipital scalp BCC shown by T1-GD w. MRI in Axial and Coronal

Fig. 3: Bony Cronal CT-Scan shows a metastatic lesion of skull by BCC.

Squamous Cell Carcinoma (SCC)

Introduction

This is the second common skin cancer, but highly curable. It originates from

Read More

keratinizing cell of the epidermis.

Etio-pathology

Risk factors are the immune-suppression, exposure to excessive sunlight, or radiation therapy. It manifests as scaly plaque crusted or ulcerated with light or whitish color.

Therapy

The main goal of treatment of BCC and SCC is total excision of the tumor, which will depend on size and location of lesions. There are some treatment options such as Mohr's micrographic surgery, surgical excision, electrodessication, curettage, carbon dioxide laser. Extension of tumor into skull, Dura or intracranial must be diagnosed by imaging studies.

Melanoma

Introduction

There are several scalp tumors, of which we will choose the melanoma, because of its increasing incidence and mortality of 40% in recent years. Cutaneous melanoma arises from epidermal melanocytes, which derives from the neural crest and produce pigment melanin.

Etio-pathology

The mechanism of developing the melanoma still remains unclear. But there are some risk factors such as presence of dysplastic or non-dysplastic nevi, presence of immune-suppression, exposure to sunshine, and family history.

There are several methods of staging melanomas such as Breslow, Clark & colleagues and TNM by AJCC (American Joint Committee on Cancer).

Clinical Finding

Clinical appearance is a light or dark pigmented lesion with irregular borders. A change in the size, shape or color of the pre-existing mole must be considered as a malignant lesion and must be histologically proved. There are four different types of melanoma shown in below table

Tab. 2 shows the different types of Melanomas

- Superficial spreading melanoma
- Nodular melanoma
- Lentigo malignant melanoma
- Acral-lentiginous melanoma

**Most common type is superficial spreading melanoma in about 60-75% ofcases*

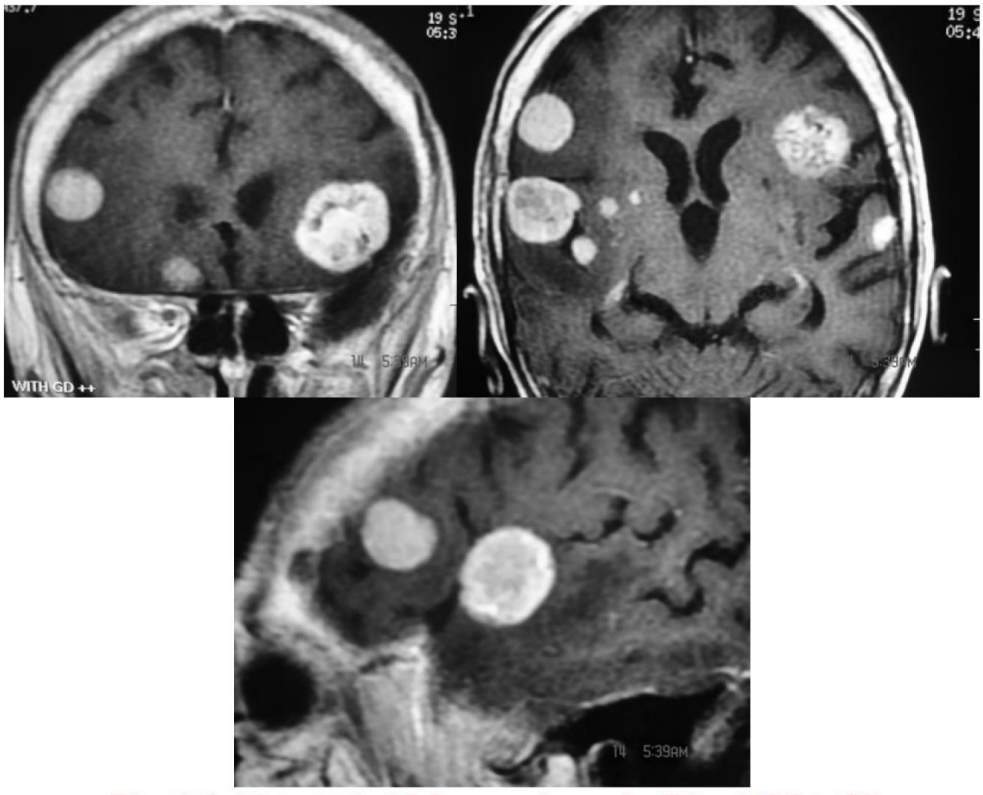

Fig. 4-6: Metastatic Melanom shown by T1w. MRI + GD on three coronal, axial and sagittal views

Therapy

Surgery with total excision of lower stage lesion is the only therapeutically option, however it will depend on the size/ shape and thickness of the tumor. Tumors with 1cm margin and (Thickness < 0.75 mm) can be considered as a thin melanoma, those with 2 cm margin and thickness between (0.75-4 mm) moderate form and those with more than 4 mm thickness is progressive form and requires a wide local skin excision.

Prognosis

There is a wide survival rate of approximately 5 years (86%) for stage I located in non-hair-bearing regions and (47%) with location in hair-bearing regions. Stage IV has a poor survival time of about 6 months. Resection of regional lymph nodes is profitable for stage I, but not for stage IV. In the case of high-stage lesion, post-operative adjuvant therapy is advocated.

Secondary (Metastatic) Lesions of Scalp

These are most common metastatic lesions of scalp deriving from several types and locations such as lung, breast, skin, and from melanomas. The treatment for these lesions depends on the location, origin tumor, clinical condition and age of patient.

Surgical therapy with post-operative radiotherapy is the best choice of treatment. The postoperative repairing of scalp defect requires the skin flaps or grafts tissue with preservation of blood supply.

Literatures

1. Stricker TP, Kumar V. Neoplasia. In: Kumar V, Abbas AK, Fausto N, Aster J, editors. Robbins and Cotran Pathologic Basis of Disease. 8th ed. Elsevier; 2010. pp. 173

2. Eskander A, Ghazarian D, Bray P, et al. Squamous cell carcinoma arising in a proliferating pilar (trichilemmal) cyst with nodal and distant metastases. J Otolaryngol Head Neck Surg 2010; 39:E63–7

3. Garg PK, Dangi A, Khurana N, et al. Malignant proliferating trichilemmal cyst: a case report with review of literature. Malays J Pathol 2009; 31:71–6

4. Rao S, Ramakrishnan R, Kamakshi D, Chakravarthi S, Sundaram S, Prathiba D. Malignant proliferating trichilemmal tumour presenting early in life: An uncommon feature. J Cutan Aesthet Surg. 2011; 4:51–5. 7.

5. PDQ- skin cancer. National Cancer Institute Resource Page. Available at http://cancernet. nci.nih.gov/clinpdq/soa/skin-cancer-physicia n.html (accessed Aug 16, 1999).

6. Miller SJ: Biology of basal cell carcinoma. J Am Acad Dermatol 24:1-13, 161-175, 1991.

7. Friedman RJ & colleagues: Basal cell and squamous cell carcinoma of the skin. In Murphy GP, Lawrence W, Lenhard RE (ed): American Cancer Society Textbook of Clinical Oncology, 2nd ed. Atlanta, GA, American Cancer Society, 1995, pp 330-341.

8. NIH Consensus Development Panel on Early Melanoma: JAMA 268:1314-1319, 1992.

9. Gilchrist BA & colleagues: The pathogenesis of melanoma induced by ultraviolet radiation. N Engl J Med 340:1341-1348, 1999.

10. Dreiling L & colleagues: Melanoma: Epidemiology, pathogenesis, and new

modes of treatment. Adv Intern Med 41:553-604, 1996.
11. Shumate CR & colleagues: The prognostic implication of location for scalp melanoma. Am J Surg 162:315-319, 1991.
12. F. Fata, E. O'Reilly, D. Ilson, D. Pfister, D. Leffel: Paclitaxel in the treatment of patients with angiosarcoma of the scalp or face. In: Cancer. Band 86, Nr. 10, 15. November 1999,[abgerufen am 16. November 2017; :768-9811

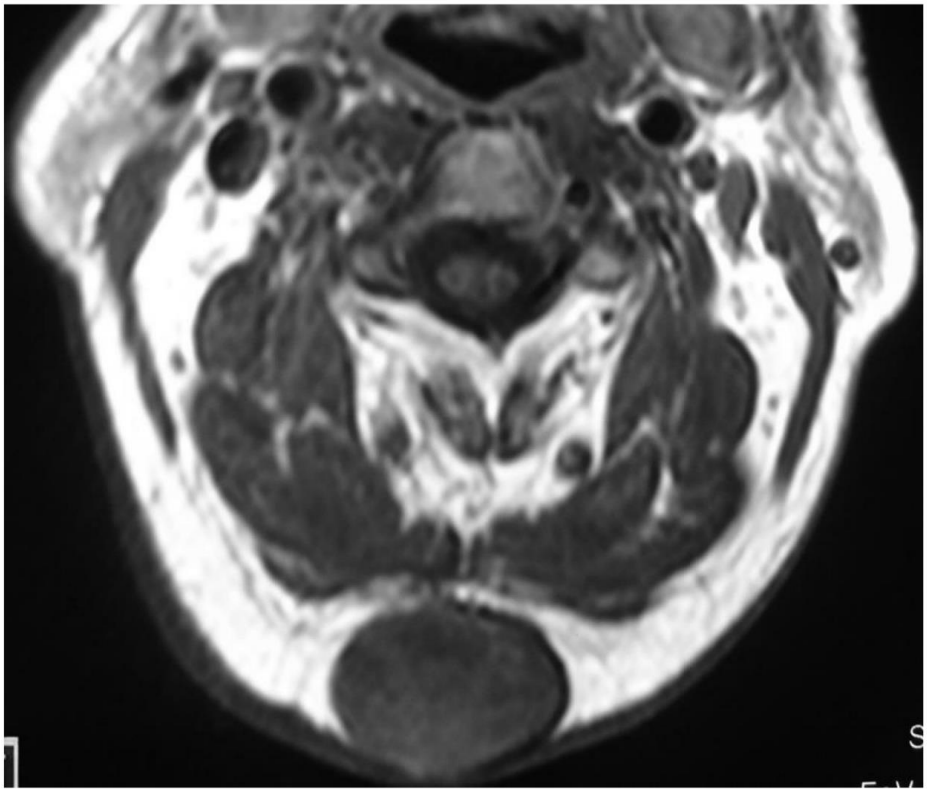

Fig. 7: Axial T1 w. &T2 w. MRI show (Scalp) tumor like sebaceous cyst